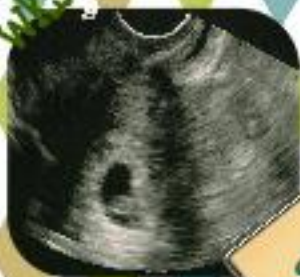
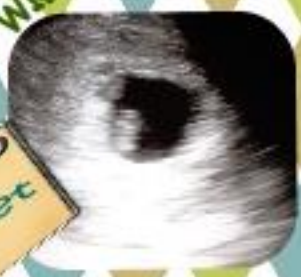
SPENCER LOUIS

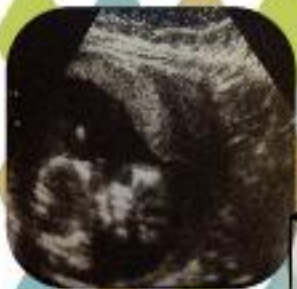6 wks



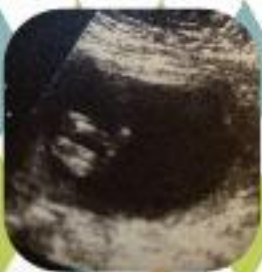7 wks



17 weeks



Face




Feet

BOY




SPENCER LOUIS

Feet

An ultrasound image showing the feet of a fetus, appearing as two small, dark, rounded shapes against a lighter, grainy background.

It's a
BOY!!

An ultrasound image showing the torso of a fetus, with a visible spine and ribcage structure.

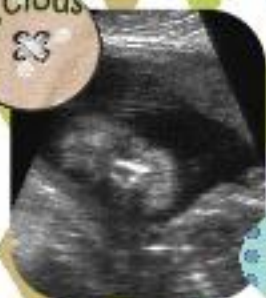Face

An ultrasound image showing the face of a fetus, with a visible profile and facial features.

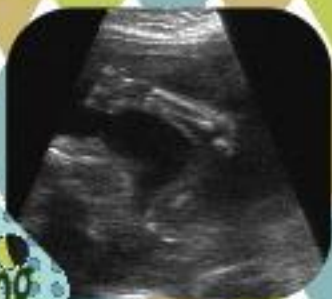19 Weeks

SPENCER LOUIS

Precious
✿



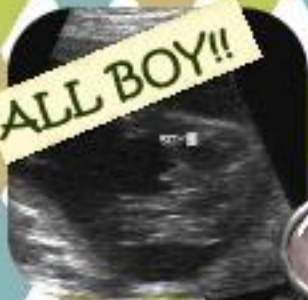Face



Profile with arm

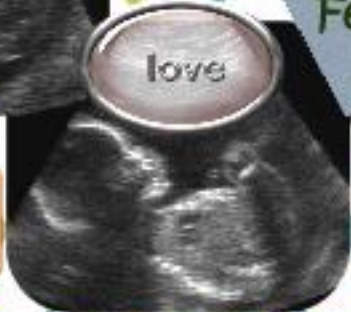Strong

ALL BOY!!



Kissable
Feet

love



cherish



23 weeks